

Abdominal Cocoon Syndrome in a Liver Transplant Patient: A Case Report and Review of the Literature

Remy Mckey, MD¹, Rim Charara, MD¹, Mohamad El Sayed, MD², Abbas Bahr, MD³

¹Department of Gastroenterology, Lebanese University, Beirut, Lebanon

²Department of General surgery, Rasoul Aazam Hospital, Beirut, Lebanon

³Department of Gastroenterology, Bahman University Hospital, Beirut, Lebanon

Corresponding author: Remy Mckey, Beirut, Lebanon, remymckey@gmail.com

doi: <https://doi.org/10.38179/ijcr.v3i1.231>

Abstract

Introduction: Cocoon syndrome is an uncommon cause of intestinal obstruction caused by the formation of a fibrous band around small intestines. It is thought to be caused by chronic peritoneal inflammation and associated with several conditions such as liver cirrhosis and liver transplantation.

Case Report: We present a case of a 72-year-old male patient who had liver transplantation three years ago for liver cirrhosis. He had an acute presentation of intestinal obstruction where a computed tomography (CT) scan showed dilated bowel loops and signs of intestinal ischemia, which warranted surgical laparotomy where the diagnosis of cocoon syndrome (sclerosing encapsulating peritonitis) was made and was then treated by adhesiolysis. No immediate or postoperative complications were documented and his life was back to normal.

Conclusion: Abdominal cocoon is a challenging diagnosis and should be considered in front of intestinal obstruction, especially in those with risk factors such as liver transplantation.

Keywords: *Abdominal cocoon, Intestinal obstruction, Liver cirrhosis, Liver transplantation, Sclerosing encapsulating peritonitis.*

Received: 2022.08.24
Accepted: 2022.10.11
Published: 2023.04.17

Financial support: None
Conflict of interest: None
Patient Consent: Written consent was obtained from the patient for the publication of this case and accompanying images

Introduction

One of the rarest causes leading to intestinal obstruction worldwide is known as "abdominal cocoon syndrome". This syndrome was first described in 1907 when it was named "peritonitis chronica fibrosa incapsulata". [1]

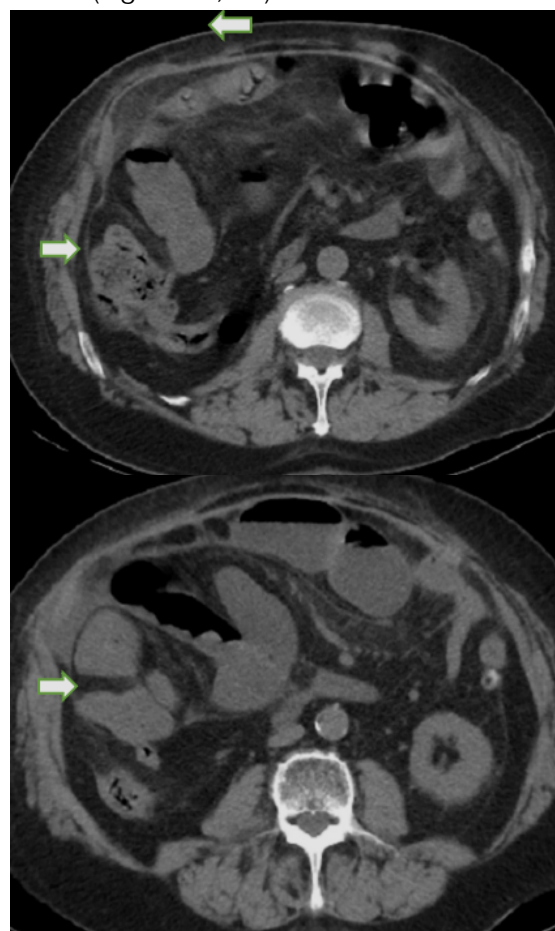
Named then as cocoon syndrome in 1978, it was considered an acquired condition resulting from an inflammatory peritoneal process where parts of the intestines are encapsulated by a fibrous membrane subsequently resulting in complete or incomplete intestinal obstruction. Patients diagnosed with cocoon syndrome present with a picture of gastrointestinal obstruction attacks with many associated symptoms such as nausea, vomiting, anorexia, loss of appetite, malnutrition, and abdominal pain. [2]

Cocoon syndrome is classified into a primary cocoon or idiopathic where the patient has no past specific medical or surgical history and a secondary cocoon where multiple triggering causes could be at the origin of this fibro-collagenous membrane such as autoimmune diseases, previous abdominal surgeries, peritonitis, beta-blocker use, infections as abdominal tuberculosis and liver cirrhosis which is the case discussed in the upcoming section. [2,3]

Case Presentation

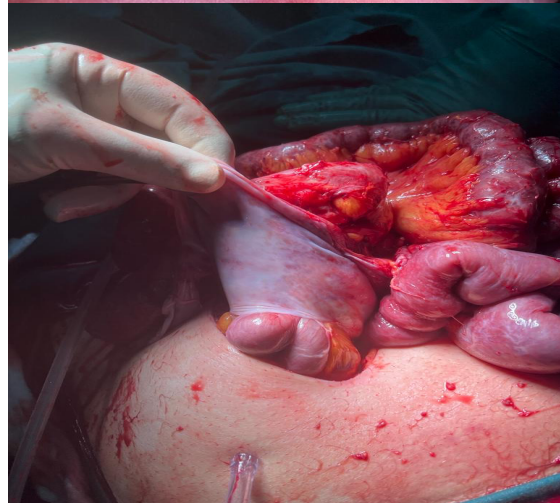
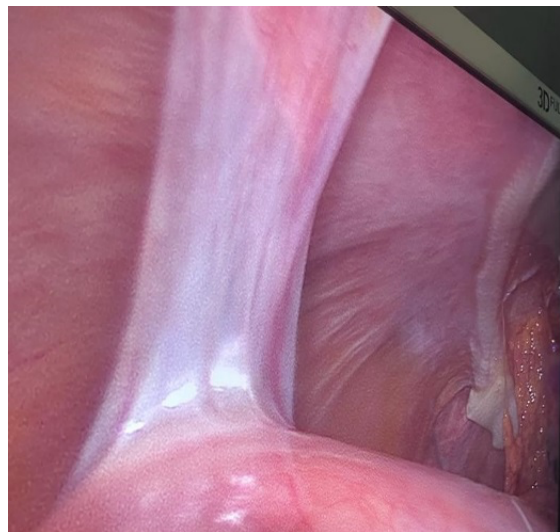
A 72 years old male patient known to have a history of non-alcoholic steatohepatitis (NASH), which is a condition caused by a build-up of fat in the liver and subsequent inflammation and formation of scar tissue, status post liver transplantation three years ago, non-smoker and non-alcoholic, presented to the emergency department complaining about obstipation and recurrent nausea and vomiting. In addition to this, he recently underwent incisional hernia repair with mesh insertion. His home medications included Prograf (tacrolimus), Certican (everolimus), calcium channel blocker, adenuric, Xarelto (rivaroxaban), and aspirin to prevent graft rejection and cardiovascular risk related to living transplantation.

At presentation his vital signs were within normal limits, he was afebrile and normotensive. Physical examination revealed moderate abdominal distention and hyperactive bowel sounds with mild diffuse tenderness on palpation. Blood tests were done and showed leucocytosis of 12,000 white blood cells (WBC) per microliter, elevated C-Reactive Protein (CRP) level 19.8 mg/L, and Creatinine 0,8 mg/dL. Other blood tests were unremarkable. An abdominal X-ray was done and showed an air-fluid level with small intestinal dilation suggestive of intestinal obstruction. CT scan of the abdomen with contrast was done and showed a prominent double loop in the right flank and right iliac fossa region confounded with an internal hernia and indicative of occlusion and obstruction, additional signs of intestinal ischemia and thickening of mesenteric fat, and multiple noncomplicated diverticula of the rectosigmoid and left colon. (Figure 1a, 1b)



Figures 1a, 1b: Contrast-Enhanced CT of the abdomen & pelvis showing clumped bowel loops enclosed in a membrane-like structure (arrows).

Laparotomy was done, and a fibrous band was found to be encapsulating parts of the small intestine as cocoon (Figure 2a, 2b).



Figures 2a, 2b: Intraoperative photographs showing the encapsulated small bowel with a dense fibrous layer.

Adhesiolysis was performed during surgery, and there were no signs of necrosis of the small bowel indicating any vascular compromise, so it was released freely without further resection (Figure 2c).

Overall, his procedure went well, and his rehabilitation went smoothly.

He was kept nothing by mouth (NPO) 24 hours after surgery then his diet was advanced as tolerated. The patient started tolerating solid foods after several days without major complaints.

As a result of the laparotomy findings and his past medical history of liver cirrhosis with

liver transplantation and his clinical picture upon presentation, patient was diagnosed with rare cocoon syndrome.

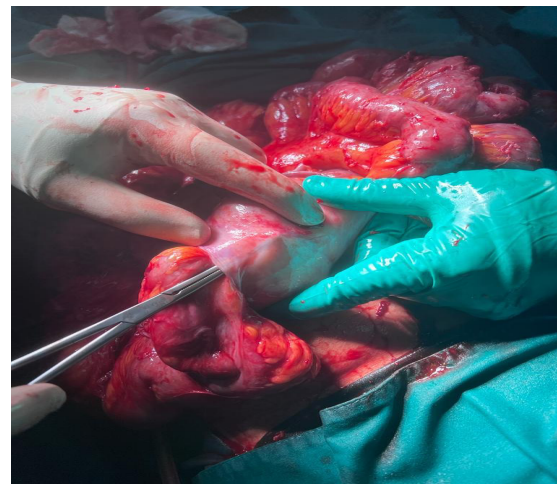

Figure 2c: Intraoperative photograph during adhesiolysis of encapsulated bowel loops

Discussion

Abdominal cocoon, or sclerosing encapsulating peritonitis is an extremely rare cause of intestinal obstruction with 6% of intestinal obstruction cases could be attributed to this condition [4].

The abdominal cocoon, first described in 1907, was named peritonitis chronica fibrosa incapsulata, but Foo et al. went on to further describe it in 1978, using the phrase "abdominal cocoon" [4]. It was mostly described in young girls in tropical and subtropical regions [5].

Cocoon is classified into primary and secondary. The primary is considered an idiopathic condition where the exact cause is still unknown but can be associated with genetic factors, whereas the secondary was attributed to multiple aetiologies such as recurrent episodes of peritonitis, peritoneal dialysis, the use of α adrenergic blockers such as practolol, beta-blockers, previous abdominal surgeries, autoimmune diseases (systemic lupus erythematosus), tuberculosis, indwelling peritoneal catheter and liver cirrhosis and liver transplantation which is the case discussed in this report. [6,7].

The pathogenesis of cocoon syndrome is described briefly by the formation of a thick

fibro-collagenous membrane in the peritoneal cavity wrapped around the small intestine leading to a total or partial encapsulation, with possible involvement of other abdominal organs such as the appendix, cecum, ovaries, and the ascending colon [6,8,10].

Cocoon syndrome is classified also according to the extent of encapsulation where in type I the intestine is partially encapsulated; type II refers to complete encapsulation of the entire intestine; and type III is a complete encapsulation of the intestine and other intra-abdominal organs [11].

A patient diagnosed with cocoon syndrome could be asymptomatic and discovered incidentally during laparotomy for any other reason or symptomatic presenting to the emergency department with an acute abdomen and a picture of acute or chronic episodes of small bowel obstruction due to the constricting cocoon band. They experience abdominal pain, nausea, vomiting, and constipation [6,9,10].

On physical exam, patients usually have asymmetrical abdominal distention, a possible feeling of abdominal mass on palpation, and hyperactive bowel sounds suggestive of an obstructing process in the abdomen [10].

These clinical findings should be correlated with a radiological assessment.

Abdominal X-rays are nonspecific for the diagnosis of the cocoon, but they can show signs of intestinal obstruction such as dilated small bowel loops and air-fluid levels [6].

The modality of choice remains the CT scan. CT scan shows dilatation of the intestines proximal to the constricting band, ascites, and mesenteric thickening. Some cases reported a cauliflower sign on CT suggestive of cocoon syndrome [9]. In our case, there were signs of intestinal occlusion with a double loop sign and infiltrating mesenteric fat that could fit with the cocoon diagnosis.

However, the final and definite diagnosis remains in laparotomy and intraoperative

findings where a fibrous band is wrapped around the small bowel or any other intra-abdominal organ, as pre-operative diagnosis of the cocoon is still not reliable and nonspecific [6,11].

Managing cocoon syndrome is relative and differs according to the severity of each presenting case. For patients complaining only of mild symptoms, conservative treatment is sufficient, such as using a nasogastric tube for decompression, bowel rest, and hydration. On the other hand, patients presenting with severe episodes of intestinal obstruction, vomiting, and anorexia will need surgical management. In this case, the best approach was to do a laparotomy, to investigate the exact cause of obstruction, followed by adhesiolysis with excision of the constricting fibrotic membrane to free the small intestines. If the entire small bowel is still viable, no need for any further resection, however any vascular compromise with resultant ischemia needs a resection of the necrotic parts. In our case, it was an acute presentation with imaging findings of intestinal obstruction with signs of ischemic compromise of some bowel loops, so the best approach was to do laparotomy and adhesiolysis of the band. Additionally, there was no need to resect any parts of the bowel since it was viable with no signs of necrosis.

The prognosis post-operation is usually excellent, as in our case, where the patient had a favorable clinical course after the adhesiolysis, and follow-up assessment after two and four weeks from discharge revealed no recurrence of symptoms and his life was back to normal [6, 9].

Conclusion:

Abdominal cocoon syndrome is a challenging diagnosis, usually associated with many eliciting causes such as peritonitis, peritoneal catheter, liver cirrhosis/transplant, and any triggering factor of peritoneal inflammation. Patients will present mostly with symptoms of intestinal obstruction and may need a radiologic assessment to document this occlusion. Treatment of cocoon is directly correlated with the extent of severity where it

ranges from conservative treatment for mild cases to surgical excision of the fibro-collagenous band in more severe cases which yields an excellent prognosis.

References

1. Lasheen O, Elkorety M. Abdominal Cocoon or Encapsulating Peritoneal Sclerosis: A Rare Cause of Small Bowel Obstruction. *EJCRIM* 2020; 7. PMID: 33313011.

https://doi.org/10.12890/2020_001972

2. Akbulut S. Accurate definition and management of idiopathic sclerosing encapsulating peritonitis. *World J Gastroenterol.* 2015;21(2):675-687. PMID: 25593498.

<https://doi.org/10.3748/wjg.v21.i2.675>

3. Kirshtein B, Mizrahi S, Sinelnikov I, Lantsberg L. Abdominal cocoon as a rare cause of small bowel obstruction in an elderly man: report of a case and review of the literature. *Indian J Surg.* 2011;73(1):73-75. PMID: 22211046.

<https://doi.org/10.1007/s12262-010-0200-7>.

4. Solak A, Solak İ. Abdominal cocoon syndrome: preoperative diagnostic criteria, good clinical outcome with medical treatment and review of the literature. *Turk J Gastroenterol.* 2012;23(6):776-779. PMID: 23864454.

<https://doi.org/10.4318/tjg.2012.0500>.

5. Makam R, Chamany T, Ramesh S, Potluri VK, Varadaraju PJ, Kasabe P. Laparoscopic management of abdominal cocoon. *J Minim Access Surg.* 2008;4(1):15-17. PMID: 19547673. <https://doi.org/10.4103/0972-9941.40992>.

6. Sharma D, Nair RP, Dani T, Shetty P. Abdominal cocoon-A rare cause of intestinal obstruction. *Int J Surg Case Rep.* 2013;4(11):955-957. PMID: 24055916. <https://doi.org/10.1016/j.ijscr.2013.08.004>.

7. Renko AE, Witte SR, Cooper AB. Abdominal cocoon syndrome: an obstructive adhesiolytic metamorphosis. *BMJ Case Rep.* 2019;12(4):e228593. Published 2019 Apr 11. PMID: 30975778.

<https://doi.org/10.1136/bcr-2018-228593>.

8. Fei X, Yang HR, Yu PF, Sheng HB, Gu GL. Idiopathic abdominal cocoon syndrome with unilateral abdominal cryptorchidism and greater omentum hypoplasia in a young case of small bowel obstruction. *World J Gastroenterol.* 2016;22(20):4958-4962. PMID: 27239122.

<https://doi.org/10.3748/wjg.v22.i20.4958>.

9. Ulusoy C, Nikolovski A, Öztürk NN. Difficult to Diagnose the Cause of Intestinal Obstruction due to Abdominal Cocoon Syndrome. *Eur J Case Rep Intern Med.* 2021;8(5):002588. Published 2021 May 12. PMID: 34123948.

https://doi.org/10.12890/2021_002588.

10. Mbanje C, Mazingi D, Forrester J, Mungazi SG. Peritoneal encapsulation syndrome: A case report and literature review. *Int J Surg Case Rep.* 2017;41:520-523. Published 2017 Nov 9. PMID: 29546031.

<https://doi.org/10.1016/j.ijscr.2017.10.058>.

11. Frazão J, Martins AR, Calado J, Godinho A. Abdominal Cocoon Syndrome: A Rare Cause of Intestinal Obstruction. *Cureus.* 2022;14(3):e22929. Published 2022 Mar 7. PMID: 35399439.

<https://doi.org/10.7759/cureus.22929>.